

Feature

Light Differential Orthodontic Mechanics (LDOM)

*This article has been peer reviewed.
Available in Spanish at www.iaortho.org.*

By Dr. Chanda Kale

Treatment planning is an integral part of any treatment and especially when it is applied in orthodontics. So many factors such as hereditary blueprints, habits, growth, pre-existing conditions, clinical condition of teeth and jaw, type of appliance selection, amount of force, potential, chief complaint, age, clinician's experience and lastly, patient cooperation, play a role in implementing proper orthodontic mechanics. Some of these factors can at best be predicted, some can be estimated and then controlled, and some can't be controlled at all. We as clinicians must do all we can to be accurate in our predictions, mechanics, and control. Therefore, we must have a goal to achieve and work toward it. This goal is partially interdependent from the patient's complaint, but is not limited to it; however, it does give clinicians a direction. Patient's complaint is quite generalized such as "My teeth are crooked," "I have buck teeth" or "I don't like spaces between my front teeth." I have yet to come across a patient who has demanded to take his teeth back by 3 mm. Our patients just assume that we, the professionals, know what to do and exactly where to place those teeth so that in the end, they will have beautifully arranged teeth.

Well, easier said than done. We know that orthodontics is a lot more than arranging teeth and we must have a plan. This plan must begin with esthetic expectations of our patient followed by re-arrangement of teeth and jaws in a stable relationship. So then, we must define a "final" position that is esthetic, stable, and functionally sound. We will then work our treatment plan so that this final position can be achieved. Our treatment plan will take into account this final position, patient's complaint, potential related to age, growth, gender, race, skeletal relationship, and enamel excess. This esthetic final position is also an anatomically correct position with teeth over their apical bases, parallel to each other with Class I cuspid relationship.

Dr. P. R. Begg¹ (Figure 1) introduced LDOM in the 50's and it has gone through changes, modifications, and refinements in its mechanics and appliance. Dr. Begg practiced LDOM with ribbon arch type bracket which changed in 1965 when Dr. Peter Kesling intro-



Figure 1 – Dr. P. R. Begg

duced 256 stamped stainless steel bracket (Begg Bracket) and then, in the 80's with Tip-Edge® bracket system that used LDOM but took it a step further making the appliance more user-friendly, accommodating cosmetic appliance considerations of our patients and permitting the clinician to finish cases "more precisely."

Dr. H. D. Kesling, an orthodontist and father of Dr. Peter Kesling, was so impressed by Dr. Begg's work that he was instrumental in bringing Dr. Begg to the USA. Dr. P. R. Begg had displayed his cases as a part of his presentation in April of 1960 at the AAO annual meeting. These were started and finished using round finishing archwire and ribbon arch type brackets. These brackets were milled from aluminum bronze and soldered to the bands. The quality of his treatment was stunning according to members of Kesling & Rocke group, who were edgewise practitioners. This was the first introduction to Begg Mechanics or LDOM in USA.

In the following years Dr. Peter Kesling used his scientific education and inventor's vision to develop the Tip-Edge® appliance that retained quality of treatment using 256 brackets, achievable mechanics in 3 goal oriented stages, and made it better by further simplifying the stages as well as giving the clinician a choice of having a rectangular or a round archwire finishing stage. Dr. Kesling called it DSAT® for Differential Straight-Arch Technique. It sort of creates a happy medium for those who practice with round stainless steel archwires (Begg) and those who are used to rectangular archwires (Edgewise).

Regardless, with Tip-Edge® and LDOM or DSAT, a clinician can treat children and adults with equal ease without changing mechanics or appliance using a light 2-4 oz. inter-arch force without extra-oral anchorage. This is possible because teeth move differentially vertically, mesio-distally and labio-lingually under light forces by tipping, uprighting, and torquing.

Bite opens by intrusion of anterior teeth rather than mechanical obstruction such as an inclined plane or a composite placed on occlusal of a molar or a functional appliance. At the same time, anterior teeth can retract reducing protrusion and uncrowd or close spaces. In skeletal Class II cases when treatment is initiated during a growth spurt, while bite is opening, teeth are uncrowding or closing spaces and protrusion is being reduced; mandibles can also

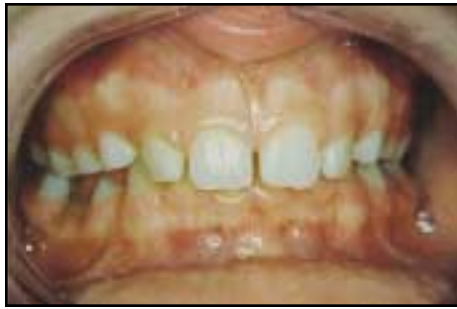

Figure 2 – Class II Div. II 100% Deep Bite

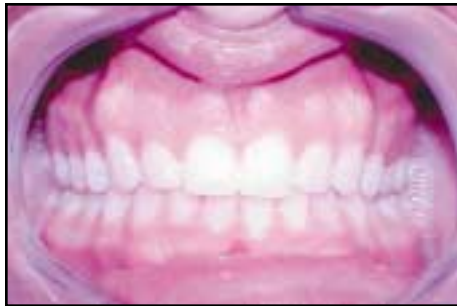

Figure 3 – Eight Year P.O. Retention

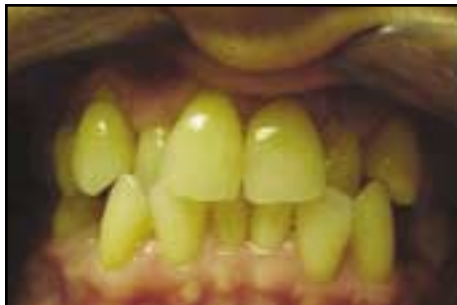

Figure 4 – Adult Class I, Severe Enamel Excess

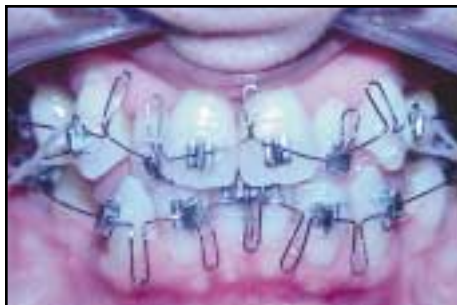

Figure 5 – Stage I Start with 256 Bracket and looped archwires

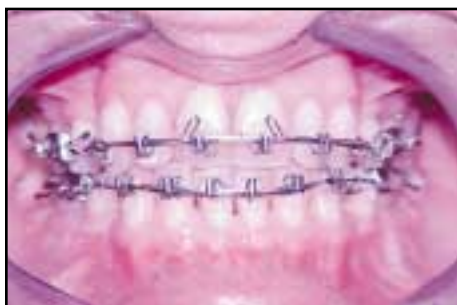

Figure 6 – Final Finishing Stage III

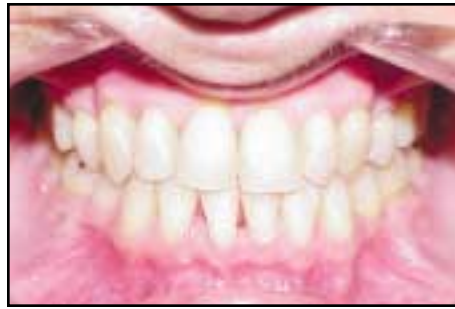

Figure 6B – One Year P.O.



Figure 7 – Attractive?

translate correcting skeletal relationship to Class I. It certainly sounds like the most wonderful orthodontic system there could be and it is, except one must do their homework i.e., Diagnosis and Treatment Planning. We must find out, what it will take to be able to create potential in a case that will allow a clinician to start directing his treatment towards that final stable esthetic position.

Today's Concept for Esthetic Profile

We are living in a world that is pleasing to our eyes: make-up, clothes, jewelry, cars, houses, buildings, skin, eyes, hair, style and yes, teeth. We want to look good. It makes an impression. It's attractive, sexy and has an appeal. Having a straight profile with nice arrangement of teeth is attractive in today's world and I don't think it is about to change in our lifetime. Looking good has always been on the top of the list for many people because it also makes them feel good, and gives them confidence in social and business life.

Orthodontically, many have defined a straight profile or esthetically

pleasing profile to have certain characteristics, which are dental and skeletal. These skeletal and dental components are obviously inter-related and also inter-dependent. For LDOM, we will discuss one of them, which is the position of the Lower Incisor to A-Pog line.²

Esthetic pleasing straight profile has been defined as "L1 to A-Pog = 0 mm." That is, when position of the Lower Incisor when on the A-Pog line, profile is considered to be the most esthetic and straight. Racial variation is a factor we need to take into account; however, we must also pay attention to patient's complaint when we apply this variation.

We follow a certain rule, which is "if you have to move the lower incisor, you will move it towards the A-Pog line." This gives us final esthetic position for the lower incisors, and we can now build our treatment plan around it. If you just visualize position of L1 in reference to the A-Pog, if L1 is behind the A-Pog line and if we must move it forward, it will create space. However, if L1 to A-Pog is in front of the A-Pog and we must move it towards A-Pog, then must have space or create some space.

In LDOM, we don't distalize molars because we know that even in the absence of attrition, there is a continuous mesial migration of dental units.⁴ We know that if we initiate treatment by preserving "E" space and with ARS3 (Air-Rotor Stripping), we will be able to treat 60-70% of cases without extractions. We also know that with our ability to be able to open bite, retract anterior teeth, and translate mandibles, we will be able to successfully treat Skeletal Class II cases without using any functional appliance. But we must know Enamel Excess in any given case to be able to make a decision on planning a treatment. We will

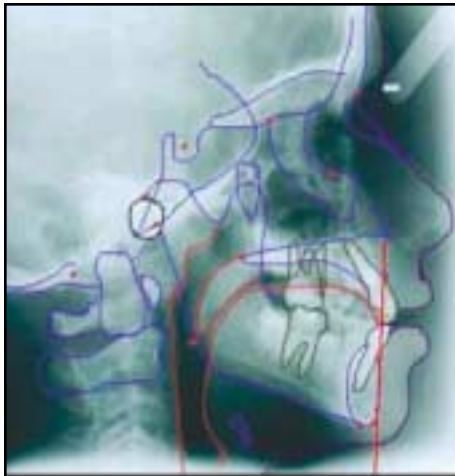

Figure 8 – L1 to A-Pog

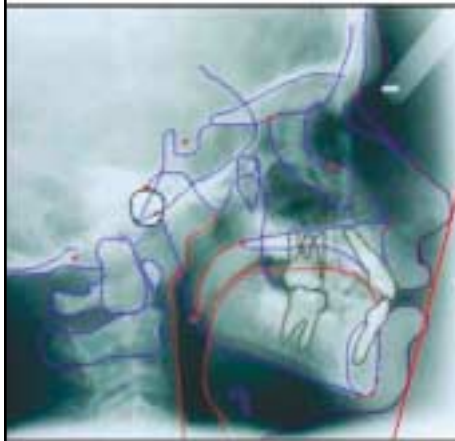

Figure 9 – Esthetic Plane

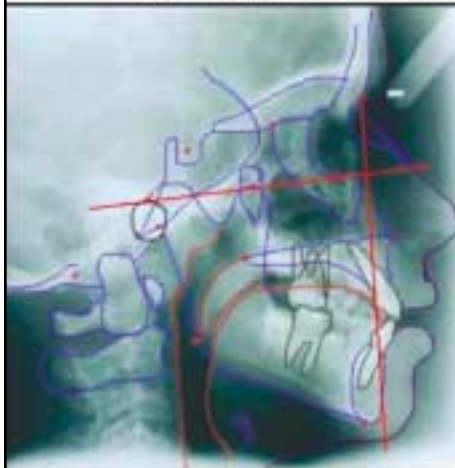

Figure 10 – Facial Analysis

use this “L1 to A-Pog” value to modify Space Analysis for the lower dentition. We will then use other factors such as Curve of Spee and Racial Averages to modify Space Analysis further to arrive at a Space Discrepancy which will give us a value for Enamel Excess.

Patient’s Complaint, Age, Growth, and Cephalometric Analysis

Correction of malocclusion, unless it is functionally debilitating and is hindering growth, is an elective procedure. Our professional ethics call upon us to consider the patient’s complaint, educate patient in differential treatment options, and allow him or her to make an educated decision as to “what is best for him/her” with our help and guidance.

When a patient wants to retract his teeth because he thinks they are sticking out, you must evaluate and determine the cause of this protrusion. Is it skeletal or dental? Skeletal Class II Div I cases have the appearance of dental protrusion. However, fault lies in the fact that the mandible is retruded. If growth permits, we may be able to intercept and translate the mandible to correct skeletal situation. When growth does not permit translation, because the patient is past puberty or is an adult, we may be able to camouflage this situation with stripping, extraction of maxillary or mandibular bicuspids or first permanent molars in non-growing, skeletal Class II and III cases.

A typical Class I case is simply “dental re-arrangement” over their apical bases with Class I cuspid guidance. We know that teeth--if not arranged over their apical bases--will relapse. Therefore, we don’t expand dental arches but allow synergistic repositioning of the dental units with precise mechanics using a light force. Teeth get re-arranged in balanced and neutral positions over their apical bases. To make this possible we reduce the Enamel Excess with stripping or extractions.

Cephalometric Analysis is not defining but merely gives us insight on skeletal condition and relationship of teeth to the bony support units. There is not one single factor which is a definitive factor in making a treatment planning decision, but information gathered in the process of Diagnosis such as Age, Growth Potential, Complaint, Space Discrepancy and Cephalometric Analysis, will allow a clinician to make a treatment plan that will fulfill patient’s requirements and treatment objectives.

So we must know:

1. Patient’s Complaint
2. Age
3. Growth Potential
4. Space Discrepancy (Measurement of space discrepancy is normally done on the mandibular arch only)
5. Cephalometric Analysis (FMA, L1 to A-Pog, WITS and U1 to SN)

We must use our professional judgment in determining the ideal time to initiate treatment, actual growth and the ability of the patient to comply with instructions.

Setting the Stage

It may appear that I am not giving a “how-to” or “recipe.” It is not my intention to withhold information but to introduce “Light Differential Orthodontic Mechanics” to readers of this journal. Articles in this journal primarily illustrate Straight Wire technique and it is not possible for you to apply this knowledge without using the right appliance or the technique. It’s impossible to summarize the technique in one article and with this article; I am merely trying to generate interest in readers to learn more about LDOM.



Figure 11 – Age 11 Skeletal Class II Div I

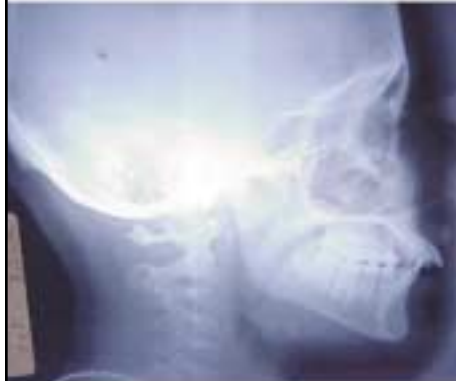

Figure 12 – Pre-Treatment Lateral Cephalogram

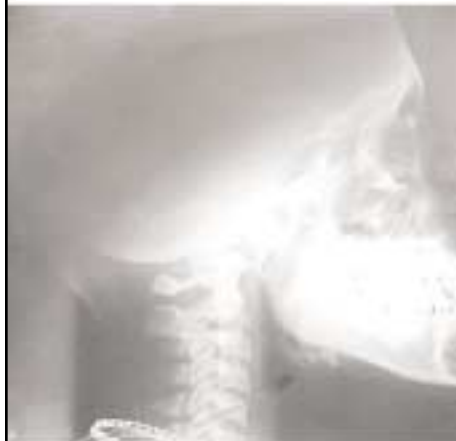

Figure 13 – Post-Treatment Cephalogram



Figure 14 – Post-Treatment

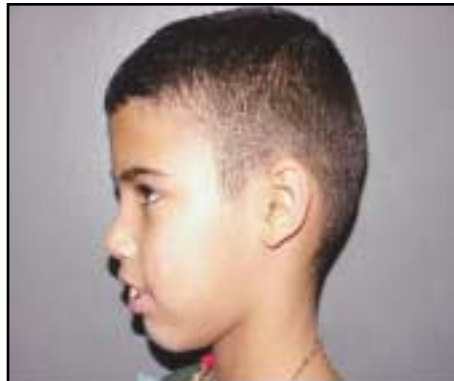

Figure 15A – Pre-Treatment Profile

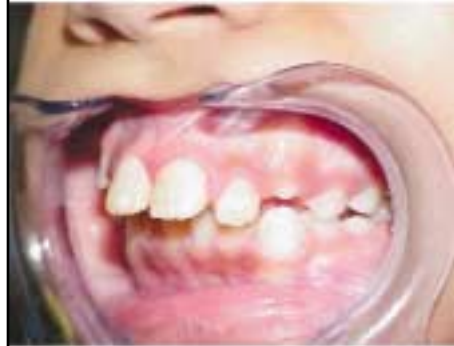

Figure 15 – Pretreatment Skeletal-Dental Class I (12-11-00)

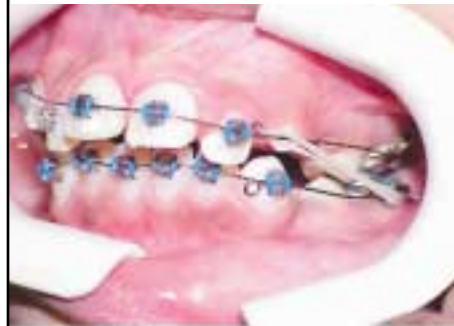

Figure 16 – Stage I with Tip-Edge® Appliance (2-5-01) Four bicuspid extractions

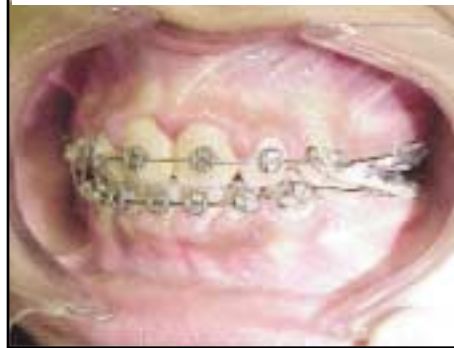

Figure 17 – End of State II, 9 months in treatment (11-15-01)

PATIENT'S COMPLAINT

Protrusion, crowding, and spacing are the most common problems that a patient would like to have corrected and they may exist alone or in combination.

For example, Skeletal Class II Div I case may have a patient complaining of having protruded maxillary teeth; however, it is the mandible that is retruded and therefore mandibular teeth are placed behind maxillary teeth. Treatment for a skeletal Class I protruded case and skeletal Class II protruded case will differ based on their age, potential for growth, and complaint.

To reduce protrusion or crowding, space needs to be created by stripping or extractions in most cases.

Skeletal Class I case is simple in a sense that bony support is exactly where it should be and it is a matter of re-arrangement of dental units and reducing enamel excess, if any.

When growth has stopped playing a role, Skeletal Class II and III cases can be treated by camouflage provided skeletal discrepancies are not over ± 10 mm (WITS).

Skeletal Class III cases, regardless of patient's complaint, should not generally be treated until patient is 18 years old. In a skeletal Class II case, growth is an advantage whereas in a Class III case, growth is a disadvantage in planning a treatment.

AGE

In Skeletal Class I cases, children or adults it is a matter of matching available space with required space. Obviously, if treatment can be initiated in mixed dentition, then the majority of the cases can be treated successfully without extractions using "E" space and ARS.

In Skeletal Class II cases, if treatment is initiated in the growth spurt, there is a very good chance that the mandible will translate (especially in horizontal growth pattern cases) restoring Class I skeletal relationship. However, as the child gets older and

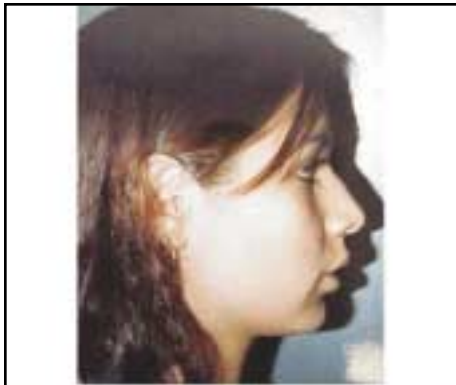

Figure 18 – Pre-Op Skeletal Class II Div I Adult

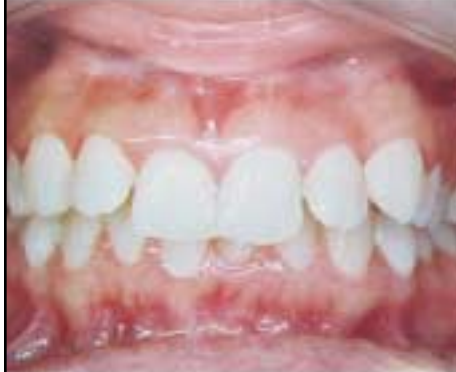

Figure 19 – Pre-Op Front-In-Occlusion

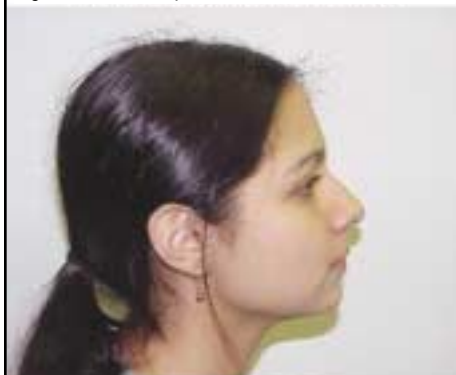

Figure 20 – One Year P.O. Profile

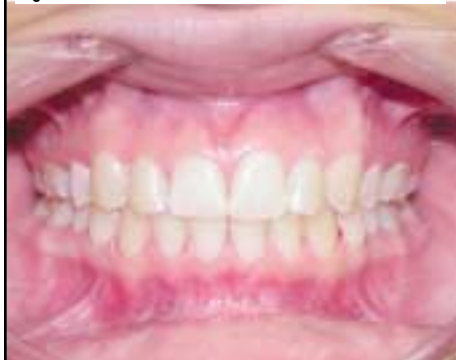

Figure 21 – One Year P.O.

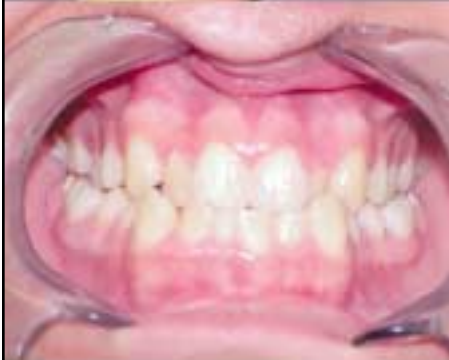
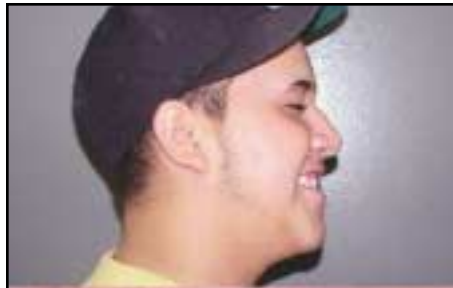
Figure 22 – Class III with Bilateral Cross Bite

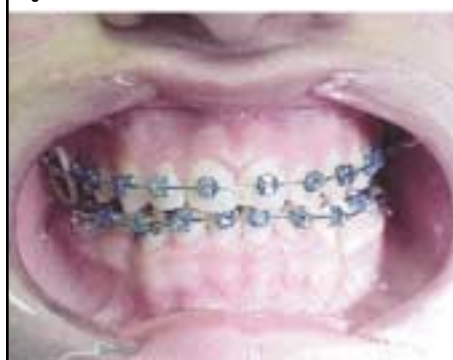

Figure 23A – One Year in Treatment with Lower Bicuspid Extractions

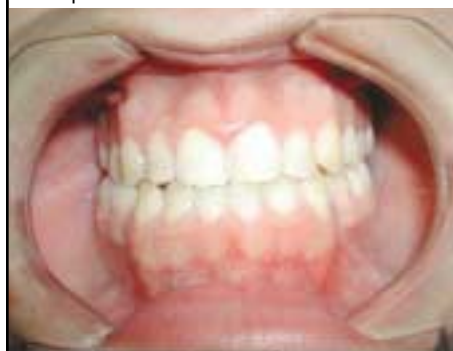

Figure 23B – Six Months P.O.

passes the puberty age, or with an adult patient, chances of translation in Class I, Div I cases diminish and now our options get limited. The patient may have a choice of camouflage or orthognathic surgery.

The reverse is true for Skeletal Class III cases. We need to wait until growth is completed to undertake the majority of these cases. Some of these cases may benefit from expansion of palate as an early treatment, but the majority will be treated when they are adult with camouflage or orthognathic surgery.

GROWTH POTENTIAL

How can we assess growth potential? We can't. However, we can make sure that we can time our treatment. We can't control growth but with orthodontic appliances, we can definitely direct it.

Our goal should be to allow growth optimally by eliminating malocclusion. In LDOM, the ideal time for beginning treatment will be when maxillary cuspids have erupted or are about to erupt within the next 3-6 months.

SPACE ANALYSIS⁵

Space Analysis is routinely done on a lower study cast only in most cases.

Procedure: Primary dentition develops when infant is 30-36 months old and the first mandibular molars erupt usually around 6-1/2-7 years of age. There are deviations in eruptions between gender as well as individual genetic patterns, however, once the first molars erupt in all four quadrants, arch length between mesial of first molars remains relatively constant. This space is premaxilla (maxilla in latin refers to jaw upper or lower). This is the only space available for anterior teeth and premolar teeth as well. This space does not increase but can be lost due to decay, premature loss of a primary molar and mesial migration of teeth and resorption of alveolar bone.

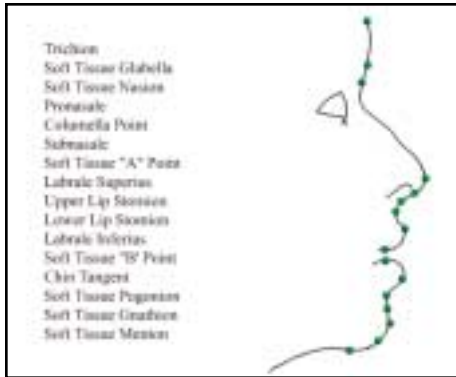


Figure 25 – Soft tissue landmarks

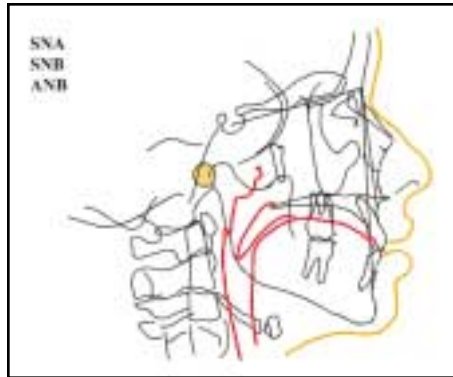


Figure 29 – Skeletal analysis

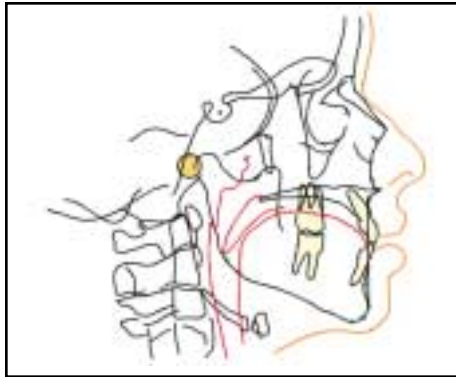


Figure 26 – Soft and hard tissue tracing

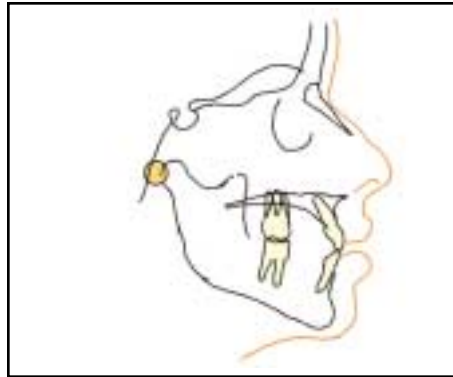


Figure 30 – UL to UN and Inter-Incisal Angle

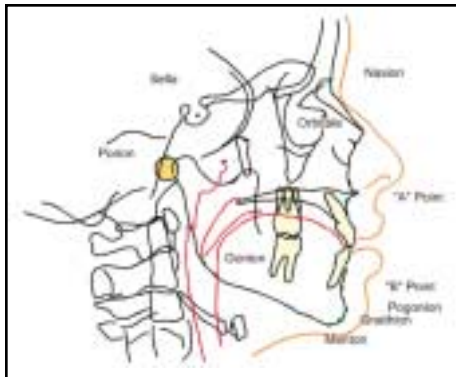


Figure 27 – Landmarks for Bigg Analysis

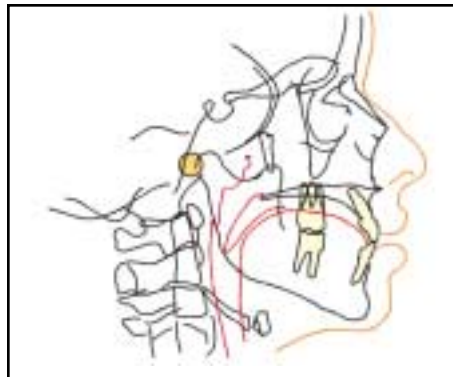


Figure 31 – Lower Incisor position relative to A-Pog

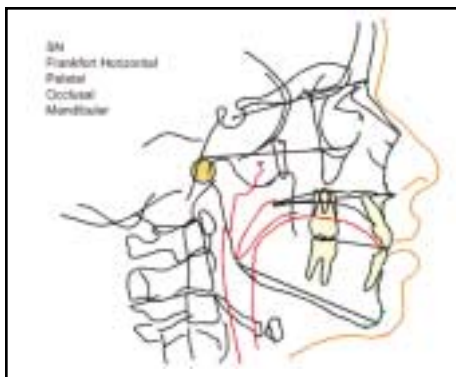


Figure 28 – Horizontal planes

This is “Space Available” (SA). It can further be modified at clinician’s discretion with predicted “Space Gained” by distalizing first molars.

“Space Required” is mesio-distal widths of teeth mesial to the first molars in the arch. A caliper is used to measure every incisor, cuspid, and pre-molar. M-D widths are added together to give “Space Required.”

Unerupted teeth are measured on a radiograph such as a periapical or a vertical bitewing and the following formula is used to calculate their relative estimated width.

X: actual size of the mandibular 1st molar

x: radiographic size of the mandibular 1st molar

Y: actual size of the un-erupted tooth

y: radiographic size of the un-erupted tooth

Formula: $Y = (y) (X/x)$

All values are taken in mm.

In an early or late mixed dentition case, either Moyer’s or Droschl’s prediction table⁶ can be used to calculate posterior enamel mass based on “Sum of Lower Incisors.”

“Discrepancy” or “Enamel Excess” can be calculated by subtracting “Space Required” from “Space Available.”

Positive value indicates excess space available and is usually manifested with spaces between teeth. Negative value indicates “Enamel Excess.”

Reduction of “Enamel Excess” can be achieved with interproximal stripping and/or tooth/teeth extractions.

D (Discrepancy) = SA (Space Available) - SR (Space Required).

Space Required can further be modified by a couple of factors such as “Curve of Spee” (deep bite) and cephalometric value (position of L1 to A-Pog).

Curve of Spee: The deeper the bite, the steeper this curve is and in extreme cases, mandibular incisors appear fan shaped and may be touching palate. Essentially, it requires space to flatten the “Curve of Spee” or to match the “Space Available,” enamel reduction is in order. To calculate additional space needed, a mandibular model is placed on a flat surface with all possible teeth touching he flat surface. The highest point of the curve is pinpointed on both sides and distance is measured from the flat surface (R & L).

The following formula is used to do the modification:

$$M = R + L - 0.5 \text{ mm}$$

Cephalometric Correction (CC): Ideally position of L1 (lower incisor) is at the A-Pog line (Point “A” – Pogonion) for maximum stability and pleasing lip

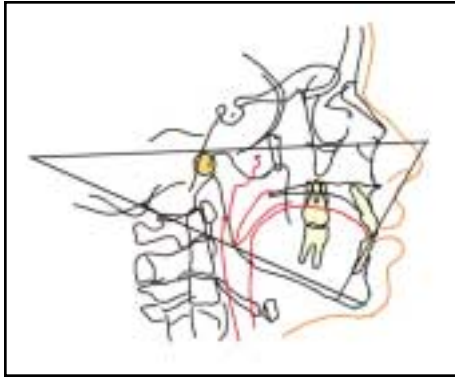


Figure 32 – Frankfort Mandibular Angle

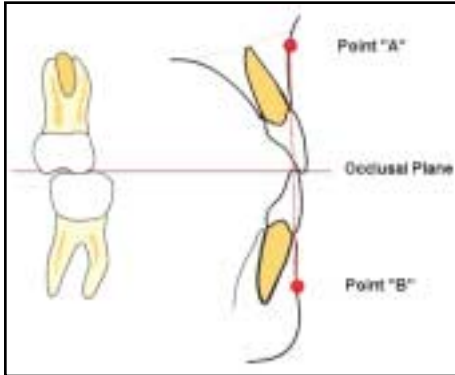


Figure 33 – WITS Class I

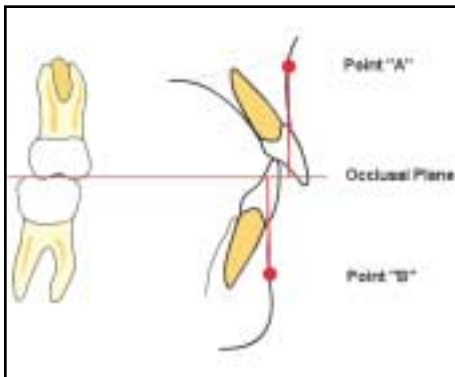


Figure 34 – WITS Class II

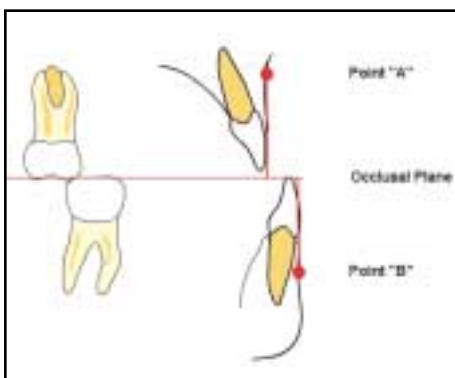


Figure 35 – WITS Class III

balance. Positive value indicates space needed to retract lower incisors towards A-Pog line whereas negative value is indicative of possible space gained by positioning lower incisor towards A-Pog line. This cephalometric measurement is multiplied by 2 for right and left sides and added to the D.

CC (Cephalometric Correction)

$$= (L1 \text{ to APo}) (2)$$

CC can further be adjusted using known norms for different races such as:

Caucasians: +1 mm

Hispanics: +3 to +4 mm

Asians: +3 mm

African-Americans: +5 to +7 mm

SR would further be modified as:

$$\text{MSR (Modified Space Required)} = \text{SR} + (\text{M}) + (\text{CC})\text{D}$$

(Discrepancy) can be calculated as:

$$\text{D} = \text{SA} + \text{SG} - \text{MSR}$$

Usually in a skeletal class I case only a lower arch space analysis is necessary and it is assumed that same conditions exist in the upper arch as well.

CEPHALOMETRIC ANALYSIS

“Cephalometric Analysis” is the term used for evaluations of growth and morphology on the basis of cephalometric tracing.

TYPICAL CEPHALOMETRIC TRACING⁷

Draw:

- Soft Tissue Profile
- Soft Tissue Tracing and Landmarks

Draw:

- Nasal spine
- Cranial Base
- Floor of orbit
- Palate
- Lateral projection of the mandible
- Central incisors
- First Molars
- Uppermost portion of Porion

Typical Begg Analysis Tracing

Mark Points:

- Sella Turcica – estimated visually to be the center.
- Nasion – represents the junction of the face and cranium.
- Porion – the top of the ear post of the cephalostat.
- Orbitale – the inferior border of the orbit as seen in the lateral radiograph.
- A Point – denotes the anterior limit of maxillary basal bone it corresponds to subspinale, the deepest concavity below the anterior nasal spine. (Horizontal to apices)
- B Point – the mandibular equivalent to point “A,” the deepest concavity on the labial surface of the image of the symphysis.
- Gonion – the midpoint of the curve of the mandible between the ramus and the lower border.
- Gnathion – the midpoint of the lower anterior curvature of the chin, midway between Pogonion and Menton. It is located by bisecting the angle formed by the facial plane and the mandibular plane.
- Pogonion – the most prominent point of the chin. It is usually located by drawing a line from Nasion tangent to the chin (the facial plane).

- Menton – the lowest point of the chin. It provides the anterior terminus of the mandibular plane.

Draw Lines:

Horizontal Planes

- SN – Sella to Nasion
- Frankfort Horizontal – Porion to Orbitale
- Palatal – ANS to PNS
- Occlusal – Incisal to distal cusps of first molars
- Mandibular Plane – Gonion to Menton

Vertical Lines

- NA – Nasion to “A” Point
- NB – Nasion to “B” Point
- U1 – Line through long axis of upper incisor
- L1 – Line through long axes of lower incisor
- A-Pog – “A” Point to Pogonion.
(Use a colored pencil for easy reference during treatment; “Blue” for pre-treatment and “Red” for post-treatment)

Measure Angles:

- FMA
- FMA (Average 25°-36°) Frankfort Mandibular Angle
- FMA determines:
- Higher Angle – Patient is more likely to have an open bite.
- Lower Angle – Patient more likely to have a closed bite.
The higher the FMA, the more likely we are to extract.

Extractions close the bite.

WITS Analysis⁸

WITS9 is measured by relating projection of “A” Point on the Occlusal Plane with projection of “B” Point on the same plane. In a Class I relationship, “A” is 0-2 mm in front of “B.” In a Class II relationship “A” is always in front of “B” by more than 2 mm and in a Class III relationship, “A” is always behind “B.”

CEPHALOMETRIC AVERAGES

U1 to SN (Average 104°) – Upper anterior are posterior or if less than 104°. Higher number indicates proclination of maxillary anteriors.

U1 to L1 (Average 135°) – Higher angle indicates more upright anteriors whereas lower angle indicates dental protrusion.

L1 to A-Pog (Average 0 mms)¹⁰ – Diagnostic Line for a pleasing esthetic profile. If you have to move lower anteriors, you move them towards the A-Pog line.

Measure labial surface of upper 1/3 of lower incisor or incisal edge (Ii) to A-Pog line.

TREATMENT GOAL

- Lower incisor 1/3 on AP line
- Eliminate Patient’s complaint
- Class I Cuspid Relationship.

References

1. Kesling Peter. *Tip-Edge Guide* (4th Edition) BB1-BB13 “A Biographical Sketch of the Man”
2. Kesling Peter. *Tip-Edge Guide* (4th Edition) CATP-1-CATP-6 “CASE ANALYSIS AND TREATMENT PLANNING”
3. Sheridan, J. J., *JCO* Volume XIX NUMBER 1 “Air-Rotor Stripping”
4. Begg P. R.; Kesling P.C.: 3rd Edition, *BEGG ORTHODONTIC THEORY AND TECHNIQUE*, SAUNDERS, 1977.
5. Graber; Vanarsdall: 2nd Edition, *Orthodontics: Current Principles and Techniques*, Mosby
6. Rakosi T.;Jonas I.; Graber T.: *Orthodontic-Diagnosis*, Thieme
7. Miyashita K.; *Contemporary Cephalometric Radiography*: Quintessence Publishing Co.
8. An Appraisal of the severity of anteroposterior jaw disharmony. Developed by the University of Witwatersand, Republic of South Africa. Kesling Peter. *Tip-Edge Guide* (4th Edition) CATP-6
9. Williams RT. The diagnostic line. *Am J Orthod* 1969;55:458-476
10. Enlow “Facial Growth” 3rd Edition; Saunders; pages 263-265



Dr. Chanda Kale

Dr. Chanda Kale graduated from the New York University Dental School in 1980 and has been in private practice since that time. He learned Begg/Tip-Edge orthodontics from Dr. Richard Conlin and now teaches with him in New York and Pittsburgh. He spoke at the IAO annual meeting this past spring on the topic of open bite and has developed a CD-ROM orthodontic course called, “Orthodontics in Your Practice.” He

also runs a forum called “Cyberdentic Orthodontic Forum” at www.cyberdentic.com/6/ubb.x. He can be contacted at ckaledds@cyberdentic.com.